

The First Sodium and Diffusion MRI during Chemotherapy of Rodent Glioma at 21T

Victor D. Schepkin¹, Cathy Levenson², William W. Brey¹, Silvia Figueiroa Da Cruz², Peter L. Gor'kov¹
¹ National High Magnetic Field Lab, FSU, Tallahassee, FL, USA, ² Florida State University, Tallahassee, FL, USA

Purpose

In-vivo MRI biomarkers for tumor therapy are powerful tools for the development of effective drugs and individualized therapies. Sodium and proton diffusion demonstrate a strong potential for assessing changes inside tumors and predicting their responses to therapy. The finding that tumor sodium content during therapy correlates with corresponding alterations of tumors' water diffusion is attracting particular attention in the efforts to understand and further develop surrogate MRI biomarkers. Concurrent observation of sodium and diffusion during glioma therapy in a model system was the subject of this MRI study. For the first time experiments of this type were performed using a record high magnet of 21.1T.

Methods

Male Fisher 344 rats with 9L glioma were subjects for the MRI study when their tumor size reached ~150 μ l (n=8). Tumor treatments were performed using chemotherapeutic agent 1,3 bis(2-chloroethyl)-1-nitrosurea (BCNU) as single IP injections (26.6 mg/kg). Animals in the control group (n=4) remained untreated. The imaging was performed using proton (900 MHz) and sodium (237 MHz) MRI with a Bruker Avance console. The unique magnet was created at the National High Magnetic Field Laboratory, Tallahassee, FL and has a bore of 105 mm. New RF probes were specifically developed for *in vivo* MRI. Three-D sodium images were acquired by a back-projection GE pulse sequence with TE/TR = 1 ms/100 ms, matrix 42x32x32, FOV 42 mm and acquisition time of 30 min. Proton diffusion mapping was performed by a DW SE pulse sequence with b1=100 s/mm² and b2=1000 s/mm², 15 axial slices, FOV 30x30 mm, slice thickness 0.7 mm, TR/TE = 3750/36 ms. All animal experiments were conducted according to the protocol approved by the Florida State University ACUC.

Results

Immediately before therapy, sodium content in the brain tumor was ~80 mM, while in the normal part of the brain it was ~50 mM. Diffusion in the tumor was also elevated (~1.2 *10⁻³ mm²/s) relative to a normal part of the brain (~0.7*10⁻³ mm²/s). Within four days after the BCNU chemotherapy, high resolution sodium images and diffusion maps revealed dramatic increases in both tumor sodium content up to ~120 mM and tumor diffusion up to ~1.7 *10⁻³ mm²/s. Additionally, non-treated tumors showed an increase of sodium content over time, but the increase took place slowly and was relatively minor. To exclude any possible partial volume effect, all sodium MR imaging scans were performed with the high resolution of 1 μ L.

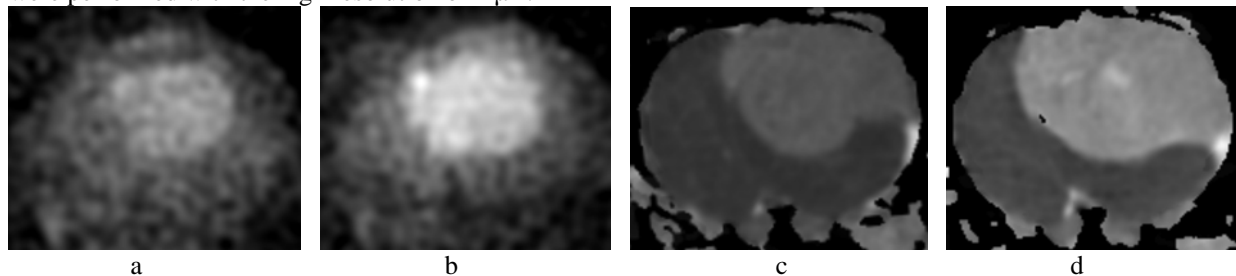


Fig. 1. *In vivo* chemotherapeutic response in rodent glioma detected by sodium (a, b) and diffusion MRI (c, d) before and four days after injection of BCNU (26.6 mg/kg).

Conclusion

The first *in vivo* large rodent MR images were acquired using 21T MRI scanner. Sodium MRI and proton diffusion demonstrate a strong correlation during therapy. Both the high field and the capability of the simultaneous use of two imaging modalities for rodent glioma are valuable tools in evaluating tumor cellular changes and developing biomarkers of tumors therapy.

Acknowledgements

Authors thanks Profs. T.L. Chenevert, B. D. Ross and A. Rehemtulla for their valuable insights; and colleagues Richard Desilets, Ashley Blue, Kiran Shetty and Nathaniel Falconer for their important help. Study was supported by NIH grant R21 CA119177. MRI imaging program at NHMFL is supported by Cooperative Agreement (DMR-0084173) and the State of Florida.